

CASE STUDY

BILATERAL THA

August 9, 2017

DR. MICHAEL WILMINK

OrthoArizona
3033 N. 44th St, Suite 100
Phoenix, AZ 85018



Issue date

01. FEB. 2018

Prepared for

JOHNATHAN SMITH

Hospital Administrator

NEXTSTEP ARTHROPEDEX LLC

1800 Triplett Blvd.

Akron, OH 44306

330.733.7600

www.nextsteparthropedix.com

iNSitu™
Hip System

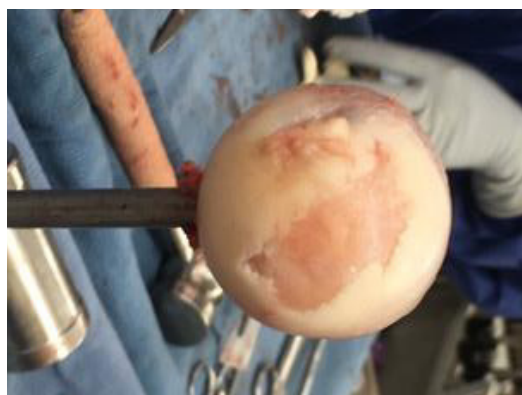
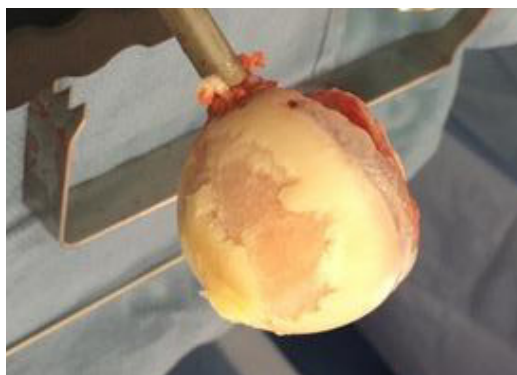

Case Study

36 year old female

"X-rays of both hips reveal bilateral hip dysplasia with moderate joint space narrowing. Both hips were injected at her first office appointment."

Patient complained of bilateral hip pain for four years. Patient states she has history of right hip arthroscopy three years prior with no relief. She was told that there was full thickness cartilage loss in her hip. There is significant pain in both hips but the right hip is more severe. Patient works as a nurse and no longer able to complete a full shift. She is no longer able to actively hike or do outdoor activities. There is significant pain in both hips that is not alleviated by anti-inflammatories. The left hip was moderately painful and was more of a deep ache. Current hip pain and symptoms are different from those she had prior to her right hip scope. There is night pain that awakens her.



MRI Right Hip:

1. No right proximal femoral fracture or AVN. Underlying bilateral developmental hip dysplasia, left greater than right.
2. Blunting and fraying anterosuperior right acetabular labrum. Right ligamentum teres femoris, transverse ligament, and capsuloligamentous structures preserved.
3. Approximate 1 cm region grade 4 chondromalacia posterosuperior humeral head articular surface. Grade 1-2 chondromalacia superior acetabular articular surface with 2 cm region degenerative-type subchondral cystic change anterosuperior acetabular margin.
4. Intact muscles and tendons without evidence of greater trochanteric or iliopsoas bursitis.
5. No significant right hip joint effusion, or distinct loose bodies in the synovial space.



📍 1800 Triplett Blvd.
Akron, OH 44306

📞 330.733.7600

🖱️ info@theken.us
www.nextsteparthropedix.com

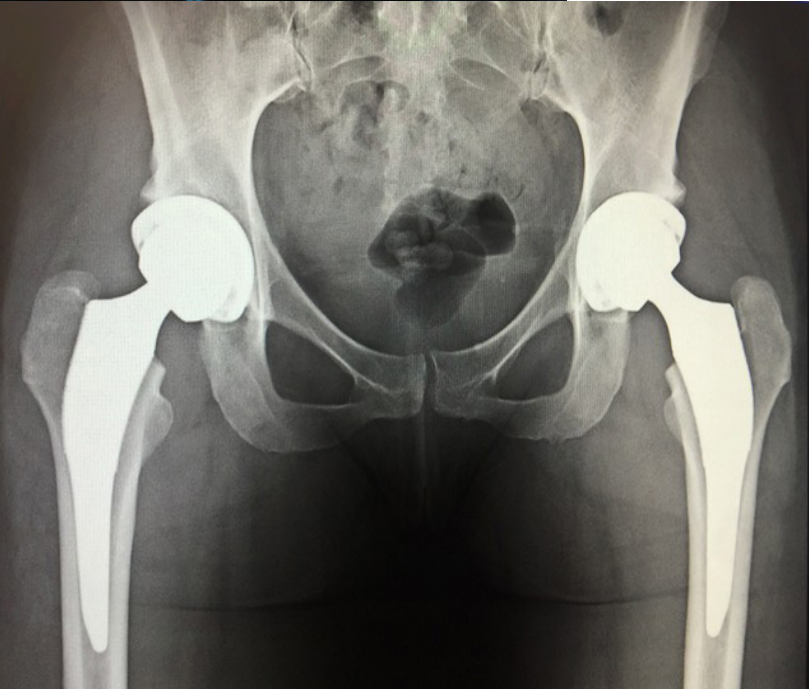
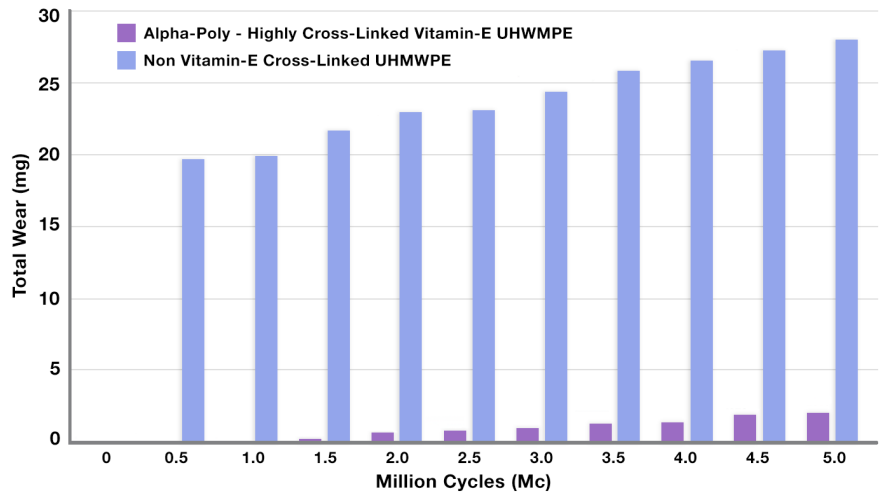


Case Study

36 year old female

Patient returned to clinic reporting only one week of pain relief after cortisone injections into each hip. After discussion of treatment options and the longevity of NextStep α -poly™, she wished to proceed with bilateral hip arthroplasty.

Wear Testing: Highly Cross-Linked Vitamin-E vs Non Vitamin-E UHMWPE



"Our poly tested so well, that I had no reservations as a surgeon offering this 36 yo patient bilateral THA at her young age... Our hip is the best option out there for younger patients needing THA."

Bilateral THA August 9, 2017.

- 200 cc blood loss total, TXA used
- Discharge home POD #2
- POD 1 Hemoglobin was 9.5, no transfusion

August 21, 2017 Post Op Clinic Visit @ 2 weeks

- Using walker for trips outside the house

September 21, 2017 Post Op Clinic Visit @ 6 weeks

- Walking without the walker
- Has returned to riding bike, hiking and back to work.

Visit us online

www.nextsteparthropedix.com





Nextstep Arthropedix LLC
1800 Triplett Blvd.
Akron, OH 44306



P 330.733.7600
F 330.733.7602



nextsteparthropedix.com
info@theken.us

Excepteur sint occaecat cupidatat non proident, sunt in culpa qui officia deserunt mollit anim id est laborum. sit amet, consectetur adipiscing elit, sed do eiusmod ex ea commodo consequat. Duis aute irure tempor incididunt ut labore et dolore magna aliqua. Ut enim ad minim veniam, quis nostrud

